



## Clinical Image

# Left-sided Gallbladder: An Unusual Intraoperative Finding

Rasul Uzdenov <sup>a</sup>, Daria Turovets <sup>b</sup>, Kseniya Zabudskaya <sup>c</sup>, Serghei Covantev <sup>d,\*</sup> 

<sup>a</sup> Department of Hospital Surgery with The Course of Anesthesiology and Intensive Care, North Caucasian State Academy, Russian Federation

<sup>b</sup> Department of Surgery, Russian Medical Academy of Continuous Professional Education, Moscow, Russian Federation

<sup>c</sup> Department of Genetics, N.N. Blokhin National Medical Research Center of Oncology, Moscow, Russian Federation

<sup>d</sup> Department of Human Anatomy, State University of Medicine and Pharmacy "Nicolae Testemitanu", Chisinau, Republic of Moldova

### ARTICLE INFO

#### Article history:

Received 21 April 2021

Received in revised form 06 May 2021

Accepted 10 May 2021

#### Keywords:

Left-sided gallbladder

Laparoscopic cholecystectomy

Anatomy

© 2021 The Authors. Published by Iberoamerican Journal of Medicine. This is an open access article under the CC BY license (<http://creativecommons.org/licenses/by/4.0/>).

## Vesícula biliar del lado izquierdo: un hallazgo intraoperatorio inusual

### INFO. ARTÍCULO

#### Historia del artículo:

Recibido 21 Abril 2021

Recibido en forma revisada 06 Mayo 2021

Aceptado 10 Mayo 2021

#### Palabras clave:

Vesícula biliar del lado izquierdo

Colecistectomía laparoscópica

Anatomía

© 2021 Los Autores. Publicado por Iberoamerican Journal of Medicine. Éste es un artículo en acceso abierto bajo licencia CC BY (<http://creativecommons.org/licenses/by/4.0/>).

HOW TO CITE THIS ARTICLE: Uzdenov R, Turovets D, Zabudskaya K, Covantev S. Left-sided Gallbladder: An Unusual Intraoperative Finding. Iberoam J Med. 2021;3(3):288-290. doi: 10.5281/zenodo.4746499.

A 62, years old female patient was admitted to the hospital for a planned laparoscopic cholecystectomy. One month earlier she was admitted with a case of acute cholecystitis and was managed conservatively. The preoperative USG demonstrated a gallbladder within normal range [70-100

mm in length and 30-40 mm in transverse diameter] with signs of cholelithiasis. There were no other abnormal instrumental or laboratory findings. The patient did not have any comorbid conditions. The intraoperative picture revealed a left-sided gallbladder (Figures 1 and 2), which

\* Corresponding author.

E-mail address: [kovantsev.s.d@gmail.com](mailto:kovantsev.s.d@gmail.com)

ISSN: 2695-5075 / © 2021 The Authors. Published by Iberoamerican Journal of Medicine. This is an open access article under the CC BY license

(<http://creativecommons.org/licenses/by/4.0/>).

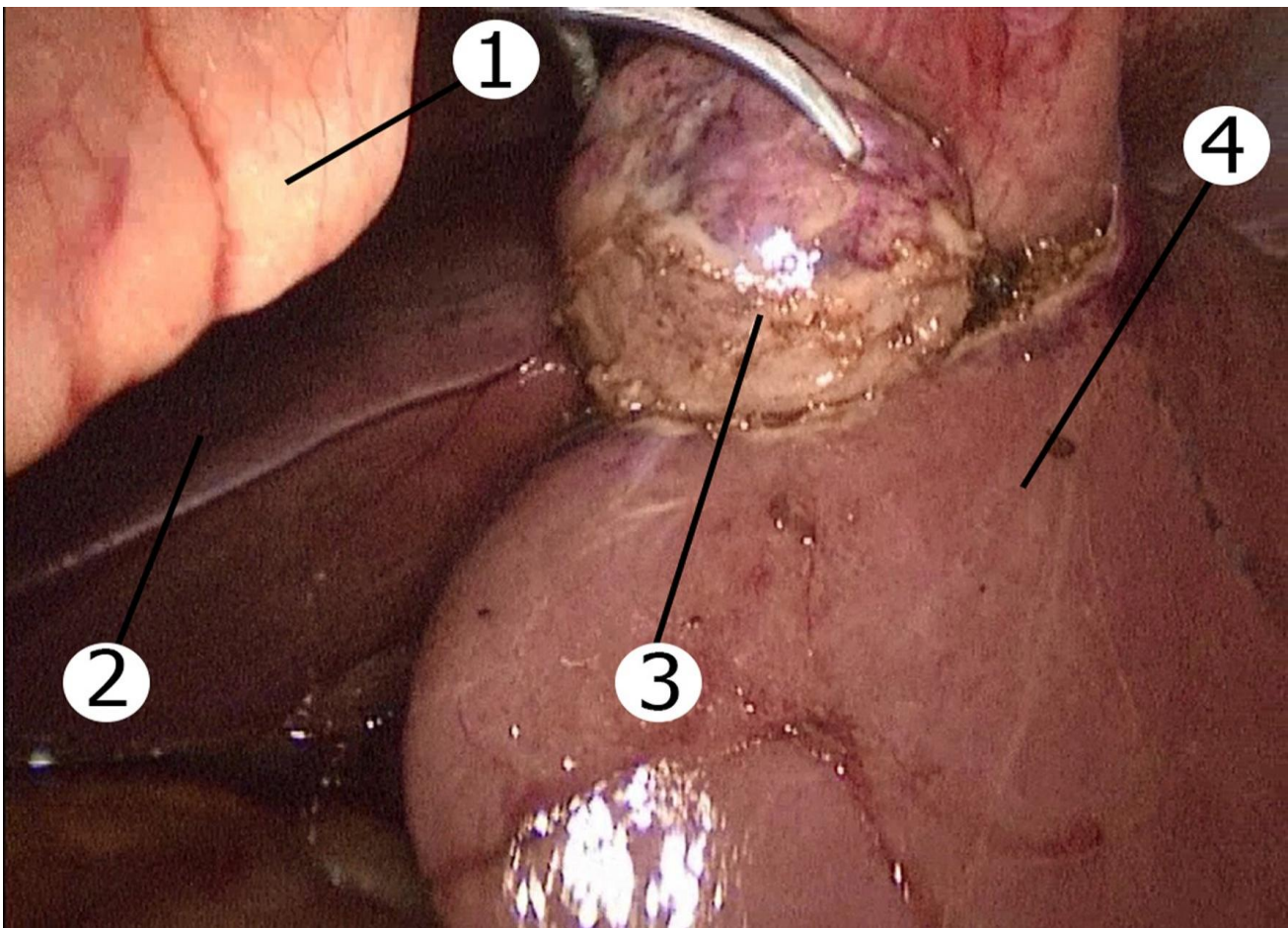
<http://doi.org/10.5281/zenodo.4746499>

made a standard procedure more complicated and required a change in the port placement. The cholecystectomy was performed without complications but required more time due to difficult dissection. The patient did not have other visible anomalies during laparoscopy.

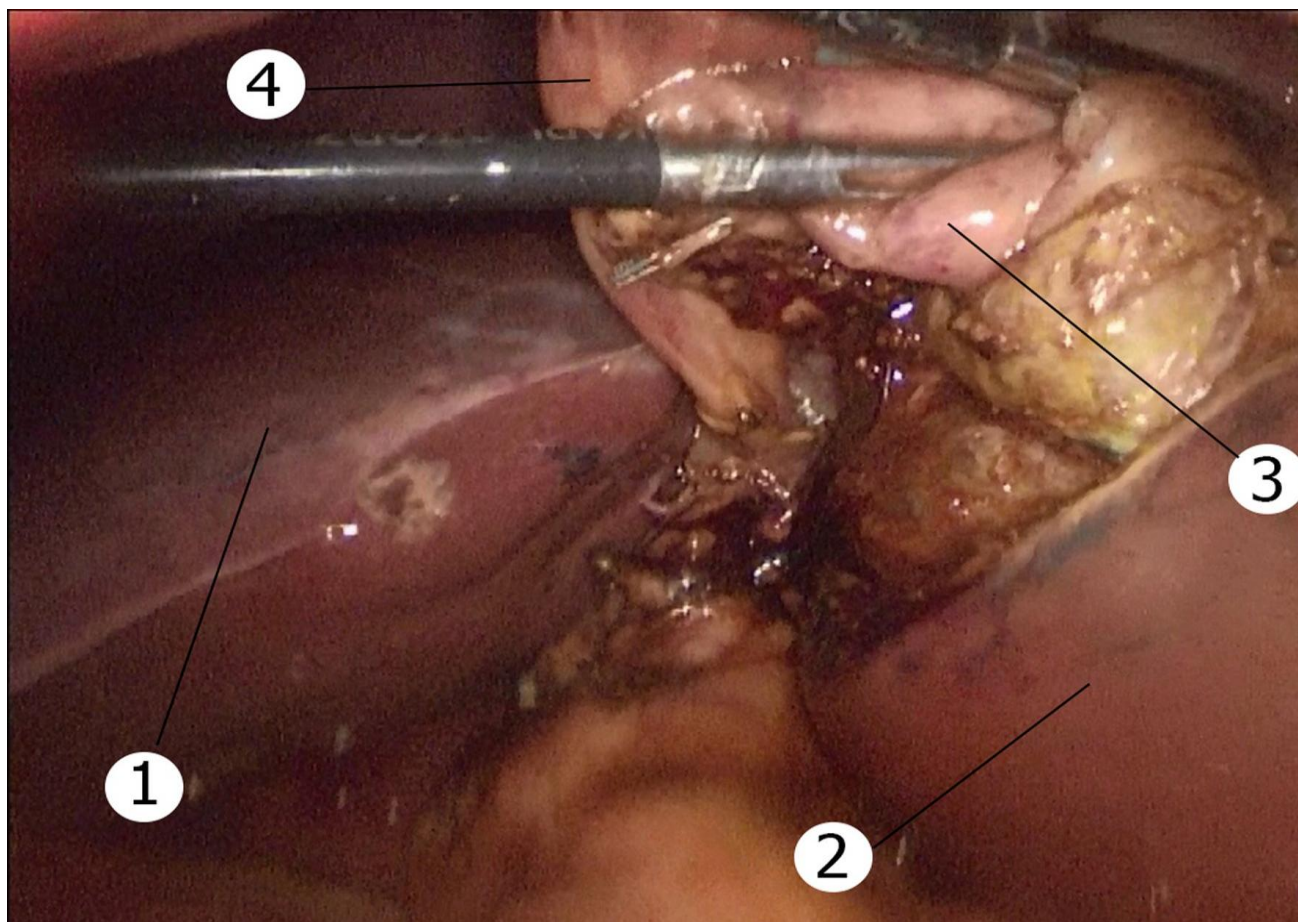
A left-sided gallbladder is a rare anatomical anomaly when the gallbladder is located on the left side of the round ligament. It was first described by Hochstetter in 1856 and the incidence is approximately between 0.1% and 1.2% [1]. There are three possible types of this anomaly: left-sided gallbladder associated with situs viscerum inversus, true left-sided gallbladder, and cases where there is an abnormal right-sided round ligament. However, true left-sided gallbladder is the rarest of these anomalies and is located under the liver segment III. Left-sided gallbladder due to right-sided teres ligament is usually located under the IVb liver segment [2]. The anomaly arises due to gallbladder migration or development of a second

gallbladder with atrophy of the original one. The main concerns during laparoscopic cholecystectomy are the necessity to change ports, modification of a standard surgical technique, and increased risk for iatrogenic injury [3]. Due to the unpredictable anatomy intraoperative cholangiography may be helpful to safely perform the procedure.

A recent systematic review and meta-analysis of fifty-three studies demonstrated that during pre-operative imaging left-sided gallbladder was reported on imaging in 29.6% patients. There were also several cases of variants of cystic union with the common hepatic duct, the most common (67.8%) of which was union on the right side of the common hepatic duct after a hairpin bend anterior to the common hepatic duct. The study also reported that 4.4% of patients had a common bile duct injury [4]. This risk can be higher and in some reports is up to 7.3% [5].



**Figure 1:** Left-sided gallbladder (intraoperative image). 1: Round ligament; 2: Right lobe of the liver; 3: Gallbladder; 4: Left lobe of the liver.



**Figure 2:** Left-sided gallbladder (intraoperative image). 1: Right lobe of the liver; 2: Left lobe of the liver; 3: Gallbladder; 4: Round ligament.

A change in port placement is one of the possible ways to improve visualization and decrease the risk of injury. The subxiphoid trocar can be moved to the left of round ligament. Alternatively the use of left subcostal and left anterior axillary line ports, or change in patient's position may improve the outcomes and provide a better view to the surgeon. If this is not possible conversion to open surgery may be required as a last resort [3]. Left-sided gallbladder is an important and rare anomaly, which is difficult to manage. Careful dissection, change of ports and management by an experienced hepatobiliary surgeon is the optimal tactic to decrease the risk of iatrogenic injury.

## 1. REFERENCES

1. Zografos GC, Lagoudianakis EE, Grosomanidis D, Koronakis N, Tsekouras D, Chrysikos J, et al. Management of incidental left-sided gallbladder. *JSLs*. 2009;13(2):273-5.
2. Nagai M, Kubota K, Kawasaki S, Takayama T, Bandai Y, Makuuchi M. Are left-sided gallbladders really located on the left side? *Ann Surg*. 1997;225(3):274-80. doi: 10.1097/0000658-199703000-00006.
3. Saafan T, Hu JY, Mahfouz AE, Abdelaal A. True left-sided gallbladder: A case report and comparison with the literature for the different techniques of laparoscopic cholecystectomy for such anomalies. *Int J Surg Case Rep*. 2018;42:280-6. doi: 10.1016/j.ijscr.2017.12.029.
4. Pereira R, Singh T, Avramovic J, Baker S, Eslick GD, Cox MR. Left-sided gallbladder: a systematic review of a rare biliary anomaly. *ANZ J Surg*. 2019;89(11):1392-7. doi: 10.1111/ans.15041.
5. Abongwa HK, De Simone B, Alberici L, Iaria M, Perrone G, Tarasconi A, et al. Implications of Left-sided Gallbladder in the Emergency Setting: Retrospective Review and Top Tips for Safe Laparoscopic Cholecystectomy. *Surg Laparosc Endosc Percutan Tech*. 2017;27(4):220-7. doi: 10.1097/SLE.0000000000000417.